



ORIGINAL ARTICLE

# Comparison of perioperative outcomes of videothoracoscopy and robotic surgical techniques in thymoma



Abidin Şehitogullari <sup>a,\*</sup>, Ahmet Nasır <sup>a</sup>, Ruchan Anbar <sup>a</sup>,  
Kemalettin Erdem <sup>b</sup>, Cahit Bilgin <sup>c</sup>

<sup>a</sup> Department of Thoracic Surgery, Sakarya University, Faculty of Medicine, Sakarya, Turkey

<sup>b</sup> Department of Cardio-Vascular Surgery, Bolu Izzet Baysal University, Faculty of Medicine, Bolu, Turkey

<sup>c</sup> Department of Chest Disease, Sakarya University, Faculty of Medicine, Sakarya, Turkey

Received 16 January 2019; received in revised form 6 April 2019; accepted 9 April 2019

Available online 30 April 2019

## KEYWORDS

Thymectomy;  
Robot-assisted  
thoracoscopic  
surgery

**Summary Objective:** In this study, the perioperative outcomes of video-assisted thoracoscopic surgery (VATS) and robot-assisted thoracoscopic surgery (RATS) were compared in patients with clinical stage I and stage II thymoma.

**Methods:** The outcomes of 24 patients (10 males and 14 females; mean age: 42.5 years; range: 18–65 years) with diagnoses of clinical stage I and stage II thymoma who underwent VATS in our clinic between April 2010 and March 2018 were compared with the outcomes of 21 patients (8 males and 13 females; mean age: 41.2 years; range: 19–63 years) with the same clinical stages of thymoma who underwent RATS between March 2013 and May 2018. The operative times, postoperative complications, lengths of hospital stay, and total amounts of chest tube drainage of the patients were evaluated.

**Results:** No postoperative mortality was observed in either group. In general, VATS was performed from the right side, and RATS was performed from the right hemithorax. The operative time was significantly longer in the VATS group than in the RATS group (106.5 min versus 75.7 min, respectively;  $p < 0.001$ ). In the VATS group, the total amount of postoperative drainage from the chest tubes was greater than that in the RATS group (210 ml versus 325 ml, respectively), and the drainage time was longer in the VATS group than in the RATS group (3 days versus 5 days, respectively;  $p < 0.001$ ). The length of hospital stay was longer for the patients in the VATS group than for those in the RATS group (5.3 days versus 4.1 days, respectively;  $p < 0.001$ ). The levels of pain were similar in both groups. No difference in the

**Abbreviations:** PET-CT, Positron Emission Tomography-Computerized Tomography; RATS, Robot-assisted Thoracoscopic Surgery; VATS, Video-assisted Thoracoscopic Surgery.

\* Corresponding author.

**E-mail addresses:** [abidin\\_sehitoglu@yahoo.com](mailto:abidin_sehitoglu@yahoo.com) (A. Şehitogullari), [dr.ahmetnasir@gmail.com](mailto:dr.ahmetnasir@gmail.com) (A. Nasır), [ruchananbar@hotmail.com](mailto:ruchananbar@hotmail.com) (R. Anbar), [drkemalettincvs@yahoo.com](mailto:drkemalettincvs@yahoo.com) (K. Erdem), [drcahitbilgin@yahoo.com](mailto:drcahitbilgin@yahoo.com) (C. Bilgin).

<https://doi.org/10.1016/j.asjsur.2019.04.005>

1015-9584/© 2019 Asian Surgical Association and Taiwan Robotic Surgery Association. Publishing services by Elsevier B.V. This is an open access article under the CC BY-NC-ND license (<http://creativecommons.org/licenses/by-nc-nd/4.0/>).

complication rates was found between the 2 groups.

*Conclusion:* In the treatment of clinical stage I and stage II thymoma patients, the robotic approach and excision with VATS are techniques with equal reliability. However, the use of robot-assisted thoracoscopic thymectomy technique is advantageous in terms of decreasing the total amount of postoperative drainage and shortening the length of hospital stay.

© 2019 Asian Surgical Association and Taiwan Robotic Surgery Association. Publishing services by Elsevier B.V. This is an open access article under the CC BY-NC-ND license (<http://creativecommons.org/licenses/by-nc-nd/4.0/>).

## 1. Introduction

Video-assisted thoracoscopic surgery (VATS) is used for the diagnosis, staging, and treatment of mediastinal masses.<sup>1</sup> Specifically, researchers have suggested that stage 1 and stage 2 thymomas can be resected using VATS.<sup>2</sup> The da Vinci robotic system (Intuitive Surgical, Inc., Mountain View, California, USA) was developed for VATS due to reasons such as limited maneuverability because of the rigid structures of the instruments and a long learning curve for surgeons. The robotic system has the advantages of providing images that are 10-times larger and three-dimensional, having instruments with very high mobility that can move in seven dimensions, the ability to provide the surgeon with an option of operating in a seated position, and a shorter learning curve for surgeons. This technology offers great advantages to thoracic surgeons, especially for the excision of lesions that are situated in regions with a narrow space and regions where important neurovascular structures are located, such as the mediastinum.<sup>3,4</sup>

## 2. Method

Between April 2010 and June 2018, the prospectively recorded data of 24 patients (13 males and 11 females; mean age: 42.5 years; range: 18–65 years) with clinical stage I and stage II thymomas who underwent VATS in our clinic were retrospectively analyzed. Likewise, between March 2013 and May 2018, the surgeries of 21 patients (8 males and 13 females; mean age: 41.2 years; range: 19–63 years) with clinical stage I and stage II thymomas who underwent RATS were analyzed. The data of the patients who underwent excision via the robotic system were entered into the database by the surgeons. All the patients' variables, including age, gender, indications for surgical treatment, excision sides, time spent by the surgeons on the console, histopathological diagnoses, chest tube removal times, lengths of hospital stay, and postoperative complications, were recorded. The study protocol was approved by the Ethics Committee of the Sakarya University, Faculty of Medicine. The study was conducted in accordance with the principles of the Helsinki Declaration.

Thymectomies with either VATS or RATS were performed on patients with a lesion diameter less than 4 cm and without invasion of any mediastinal vascular structures. In patients diagnosed with myasthenia gravis (MG), thymectomy with the robot system was recommended if the

procedure was expected to benefit evaluations of variables such as positive anti-acetylcholine receptor antibodies, negative anti-muscle specific kinase receptor antibodies, and positive titin antibodies, and if thymectomy was expected to benefit individuals with limited diseases, such as ocular myasthenia, as diagnosed by a neurologist. Patients with comorbid diseases (i.e., hypertension, MG) underwent surgical treatment after these diseases were controlled. Preoperative thoracic computed tomography (CT) (Fig. 1A), positron emission tomography-computerized tomography (PET-CT), pulmonary function test results, routine whole blood values, and the biochemical values of the patients were reviewed. After informing the patients of the advantages and disadvantages of the VATS and robotic system approaches and after obtaining informed consent from the patients, the decision to perform excision with the use of VATS or the robotic system was determined.

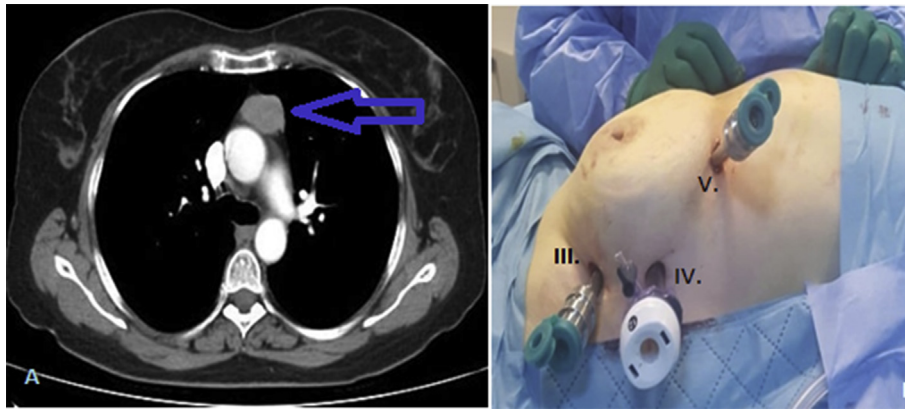
The ages, genders, surgery sides, operative times, tumor stages, lengths of hospital stay, total postoperative chest tube drainage amounts, durations of tube placement, and postoperative complications of all the patients were compared.

### 2.1. Video-assisted thoracic surgery group

Following the administration of general anesthesia, all of the patients were intubated with a double-lumen endotracheal tube. The patients were placed in the supine position and were slightly elevated on the operating table by supporting the right lower side of the thorax. The table was rotated 30° towards the surgeon, and the right arm of the patient was hyperextended. Three ports were introduced around the right breast. An additional 4-cm utility thoracotomy incision was made. The mediastinal pleura was opened using cautery, and the left hemithorax was entered. The bilateral mediastinal pleura was opened, and the mass, thymus, and adipose tissue were resected en bloc. After resection, the mass, thymus, and adipose tissue were removed and placed into an endobag. The operation was completed by transmediastinally inserting a thoracic drain through the intercostal space.

### 2.2. Robot-assisted thoracic surgery group

Following the administration of general anesthesia, a double-lumen endotracheal tube was inserted into all of the patients. The patients were positioned on the operating table by elevating the right side. Three incisions were made around the mammary gland. A 12-mm trocar was



**Figure 1** A-Preoperative computed tomographic scan of a 60-year-old woman with a suspected thymoma. B-Patient position (30° right side up). Port placement for RATS thymoma resection (III. Intercostal space, IV. Intercostal space, V. Intercostal space).

introduced through the 4th intercostal space in the right anterior axillary line. An 8-mm trocar was introduced through the 3rd intercostal space at the anterior position of the axillary line, and the other trocar was introduced through the 5th intercostal space between the anterior axillary line and the midclavicular line (Fig. 1B). All trocars were connected to the robotic arms. CO<sub>2</sub> insufflation was used for patients with large amounts of adipose tissue. A mediastinal pleural incision was then made. The mediastinal pleura was dissected beginning from the caudal region and advancing in the cranial direction (Fig. 2A). The veins of the thymus gland were located and dissected without damaging the innominate vein. These thymic veins were clipped and incised. Both thymic poles were mobilized over the innominate vein. The upper poles were gently pulled down after the dissection. The thymus tissue, which was resected en bloc to include the surrounding adipose tissue, was removed and placed into an endobag from the incision in the middle region (Fig. 2B). A thoracic drain was transmediastinally inserted through the intercostal space, and the incisions on the thorax were closed.

In the postoperative period, the patients in both groups were transferred to the intensive care unit. The next day, they were discharged from the intensive care unit and transferred to the ward if no contraindications were noted.

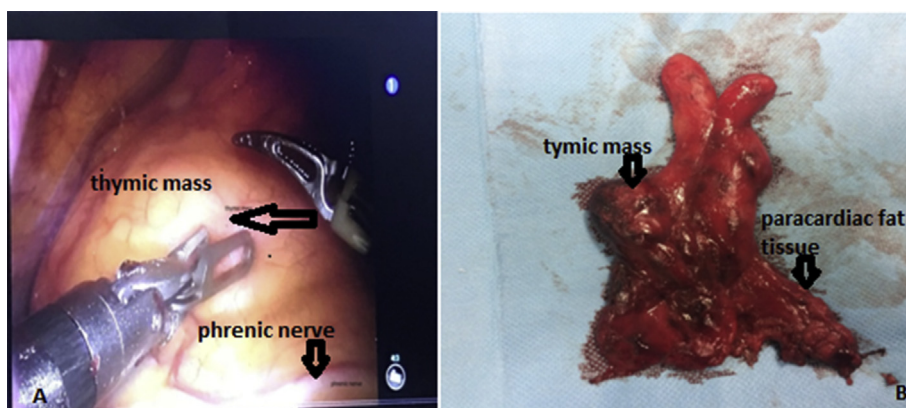
During the first two days of the postoperative period, tramadol and paracetamol were intravenously administered. During the subsequent days, only paracetamol was administered. Twenty-four-hour chest tube drainage amounts were recorded daily. The tubes were removed when the daily drainage amount was 100 cc or less.

### 2.3. Statistical analysis

The statistical analyses were performed using SPSS version 11 software. The mean  $\pm$  standard deviation (or the mean and standard error) was calculated for the numerical values, and Student's t-test or the Mann-Whitney U-test was performed to compare both groups. The categorical variables of the 2 groups were compared using Pearson's chi-square test. If p values were below 0.05, the differences were considered statistically significant.

## 3. Results

The age, sex, tumor stage, comorbid diseases, and FEV1 ratios of the patients in the VATS and RATS groups were similar (Table 1). Clinical stage III patients who received sternotomy operations in our clinic were excluded from the



**Figure 2** A-Dissection of the right-side mediastinal pleura, parallel to the right phrenic nerve, provides visualization. B-The thymus after robotic thymectomy.

**Table 1** Clinical characteristics of patients who underwent thoracoscopic and robotic thymectomies.

	VATS Group (n = 24)		RATS Group (n = 21)		P
	n	Mean ± SD	n	Mean ± SD	
Age (years)		42.52 ± 7.45		41.29 ± 7.05	0.42
Sex (female/male)	14/10		13/8		0.33
Laterality (right/left)	24/0		19/2		0.48
Forced expiratory volume in 1st second (%)		80.31 ± 16.21		83.36 ± 11.41	0.52
Stage I (Masoaka)	11		9		
Stage II (Masoaka)	12		11		
Stage III (Masoaka)	2		—		
Who histological classification					
Type A	8		9		
Type AB	4		3		
Type B1	5		6		
Type B2	6		2		
Type B3	1		1		
Tumor size (mm)	27.3 ± 5.7		25.8 ± 5.6		0.53
Myasthenia Gravis	5		4		
Hypertension	3		2		

study. Nine of the patients who had indications for excision via minimally invasive surgery had a diagnosis of MG. Of these patients, 5 underwent VATS and 4 underwent RATS. No patients required conversion to open surgery due to a major intraoperative complication, such as bleeding.

The mean operative time was 106.5 min in the VATS group and 75.7 min in the RATS group ( $p < 0.001$ ). The volume of intraoperative blood loss did not differ significantly between the two groups (Table 2). None of our patients developed a myasthenic crisis. According to the Masaoka staging system, thymomas were identified in 44% of stage I patients, 51% of stage II patients, and 4% of stage III patients. In the VATS group, histopathological types A, AB, B1, B2, and B3 were found in 8, 4, 5, 6, and 1 patients, respectively, according to the WHO histological classification. At the same time, 11, 12, and 2 patients had Masaoka stages 1, 2 and 3 disease. Five patients had MG. In the RATS group, 9, 3, 6, 2 and 1 patients were histopathologically diagnosed with types A, AB, B1, B2, and B3, respectively, according to the WHO histological classification. Nine and

11 patients had Masaoka stages 1 and 2 disease. Four patients had MG. All of the patients were transferred to the intensive care unit on the day of the operation. The following day, they were transferred to the normal ward. Four patients postoperatively received intensive care support for an extra day. The mean length of the hospital stay was calculated to be 5.7 days in the VATS group and 4.1 days in the RATS group ( $p < 0.001$ ) (Table 2). The postoperative pain and remission rates were similar between the 2 groups. After RATS, the duration of pleural drainage was shorter compared to the VATS group (3 days versus 5 days, respectively;  $p < 0.001$ ), and the pleural drainage volume was lower in the RATS group than that in the VATS group (210 ml versus 325 ml, respectively;  $p < 0.001$ ).

Five (11%) patients developed postoperative complications. In the VATS group, one patient developed diaphragmatic eventration due to a left phrenic nerve injury, and two patients developed pulmonary atelectasis in the postoperative period. In the RATS group, one patient developed pulmonary atelectasis and one patient developed

**Table 2** Comparison between operative and postoperative variables in groups.

	VATS Group (n = 24)		RATS Group (n = 21)		P
	n	Mean ± SD	n	Mean ± SD	
Duration of operation (min)		106.52 ± 26.68		75.70 ± 38.08	<0.001
Amount of total drainage from chest tubes (ml)		325.45 ± 25.38		210.34 ± 20.22	<0.001
Duration of postoperative pleural drainage (day)		5.10 ± 3.21		3.10 ± 2.2	<0.001
Duration of hospital stay (days)		5.76 ± 1.27		4.16 ± 1.15	<0.001
Operative blood loss (ml)		92.6 ± 30.1		68.4 ± 18.6	=0.151
Complications (no/yes)	21/3		19/2		0.49
Phrenic nerve injury	1		—		
Pulmonary atelectasis	2		1		
Pneumonia	—		1		
Recurrence	2	—			
Laterality (right/left)	24/0		19/2		0.48



pneumonia in the postoperative period. When the complications were evaluated according to the Clavien-Dindo classification after the surgical procedures, 5 patients had grade I complications. Antibiotic changes were applied in patients with pneumonia. Blood loss was not sufficient to require postoperative transfusion or reoperation. No postoperative mortality was detected. Eleven patients underwent adjuvant postoperative radiotherapy due to the presence of capsular invasion. During the follow-up period, 2 patients in the VATS group underwent open revision surgeries for a prediagnosis of recurrence. No recurrence was identified in the other patients. The mean follow-up period was 28 months. The patients were followed up with the use of regular annual computed tomography.

#### 4. Discussion

Thymoma surgeries should be performed in accordance with oncological principles due to the potential for malignancies.<sup>5</sup> Therefore, patients should be carefully selected for thymoma resections performed thoracoscopically and robotically. Considering the morbidity and cosmetic results associated with the transsternal approach, the surgical approach should be as minimally invasive as possible when thymectomy is indicated. However, the choice among these minimally invasive techniques depends on the experience of the surgeon and the facilities of the institution.<sup>6,7</sup> Compared with VATS thymectomy, robotic thymectomy results in significantly fewer complications, such as the need for revision surgery due to incomplete resection and vascular injury, while the rates of intercostal neuralgia and brachial plexus injury have been reported to be higher.<sup>8,9</sup> None of our patients had a vascular injury. Only one patient who underwent VATS developed left diaphragmatic paralysis due to a left phrenic nerve injury.

The minimally invasive transsternal approach has been accepted as the gold standard for thymus resection.<sup>1,10</sup> In recent years, thymectomy has been performed using both robotic and thoracoscopic approaches in the thoracic area. In publications on the use of VATS and RATS thymectomies, the lengths of hospital stay were reportedly shorter, respiratory functions were better preserved, and the operative trauma was minor.<sup>11,12</sup> In the literature, the robotic approach has been compared with both VATS and transsternal approaches in stage 1 and 2 patients diagnosed according to the Masaoka staging system for thymomas. Compared with the VATS approach, the length of the hospital stay, the amount of postoperative pleural drainage, and the rate of conversion to open surgery were found to be significantly lower in patients who underwent robotic surgery, whereas the cost of robotic surgeries was reported to be higher, and no early recurrence was observed in either of the 2 groups.<sup>13,14</sup>

Ye et al. found that in the RATS group, the mean postoperative hospital stay was shorter (3.7 days in the RATS group and 6.7 days in the VATS group), and the mean postoperative pleural drainage volume was significantly decreased (1.1 days vs. 3.6 days)<sup>16</sup> (Table 3). In our clinic, the mean length of hospital stay was shorter in the RATS

group than that in the VATS group. Likewise, the amount of pleural effusion drainage was found to be significantly lower in the RATS group. We think that several reasons may explain why the pleural drainage volume was low. First, the improved dexterity of instruments that can articulate with 7° of freedom and rotate 360° allows complex 3-dimensional movements superior to those permitted by conventional minimally invasive instruments, enhances dissection safety around vessels and nerves, and is more comfortable in small, remote areas such as the superior horns or the contralateral mediastinum. Second, the high-resolution, 3-dimensional real-time video image permits an optimal magnified view of the surgical field.<sup>11</sup> Third, the filtering of hand tremors allows greater technical precision.<sup>17</sup> None of the patients required conversion to open surgery or blood transfusions. Our results demonstrated the safety and efficacy of robotic thymectomy for early-stage thymoma.

However, some authors have reported a local recurrence rate of 3.4% in patients who underwent VATS thymectomy. Some authors have also compared VATS thymectomy with transsternal thymectomy in their studies but did not identify recurrence for stage II thymoma in the transsternal or VATS groups.<sup>15</sup> Another study reported no significant difference in disease recurrence or overall survival between the two groups.<sup>18</sup> However, the risks of tumor capsule rupture and the spread of tumor cells to the pleura during thymoma resection reflect the controversial suitability of the VATS approach.<sup>19</sup> Indeed, in a case series study published in 2000, both local and pleural recurrences were reported in thoracoscopy incisions following thymoma resection.<sup>1</sup> With both surgical techniques, complete removal of the thymic tumor and the entire mediastinal tissue must be ensured to provide remission, especially in patients with MG.<sup>20</sup> We detected recurrence in one of the patients who was followed up in the second postoperative year, and we also detected recurrence in another patient who received a follow-up four and a half years later. We performed transsternal resections with open surgery. Both of these patients were in the VATS group. We did not identify recurrences in the other patients. The superiority of robotic surgery in accessing and maneuvering in the surgical site compared to VATS, as well as its high resolution, safe manipulation, and technical superiority, highlights the benefits of the robotic approach.

Robotic thymectomy was performed using the right or left transthoracic or subxiphoid partial transthoracic approaches. In a 14-patient series with the right approach, the mean length of the hospital stay was 2 days, the mean morbidity rate was 7%, and the mean operative time was 96 min. In a series of 33 patients who underwent the left hemithorax approach, the mean operative time was 120 min, the mean length of the hospital stay was 2.6 min, and the mean morbidity rate was 6%.<sup>11,21</sup> In another study, the authors performed a retrospective analysis of the results of 74 consecutive robotic thymectomies compared with those of 79 thoracoscopic thymectomies. No significant differences were found in the conversion rate, operative time, and postoperative complications, but an improved outcome was achieved for myasthenic patients

**Table 3** Comparison of published studies with our results which are compared VATS and RATS.

Author, date and Study type	Patient group	Outcomes	Key results	Comments
Ye B et al., (2013), World J Surg Oncol <sup>16</sup>	Video-assisted thoracoscopic surgery versus robotic-assisted thoracoscopic surgery in the surgical treatment of Masaoka stage I thymoma	Postoperative pleural drainage (days) Postoperative hospital stay (days)	VATS 3.6 ± 1.2 RATS 1.1 ± 1 P < 0.01 VATS 6.7 ± 1.4 RATS 3.7 ± 1.1 P < 0.01	RATS is equally minimally invasive as VATS and results in a shorter drainage period and reduced hospital stay compared with the VATS approach.
Rückert JC et al., (2011), J Thorac Cardiovasc Surg <sup>22</sup>	Comparison of robotic and nonrobotic thoracoscopic thymectomy	Operative time (min)	VATS 198 ± 48 RATS 187 ± 48 P < 0.01	The duration of surgery did not differ significantly in the robotic and thoracoscopic groups.
Qian L et al., (2017), J Thorac Dis <sup>23</sup>	A comparison of three approaches for the treatment of early-stage thymomas	Postoperative pleural drainage (days) Pleural drainage volume (mL)	VATS 3.8 RATS 2.9 P < 0.001 VATS 613.9 RATS 352.2 P < 0.001	RATS is less invasive than VATS with a shorter postoperative pleural drainage duration time, a reduced drainage volume, and a shorter hospital stay.
Our results	Comparison of perioperative outcomes of videothoracoscopy and robotic surgical	Operative time (min) Postoperative pleural drainage (days) Postoperative hospital stay (days) Pleural drainage volume (mL)	VATS 106 ± 26 RATS 75.7 ± 38 P < 0.001 VATS 5.1 ± 3.2 RATS 3.1 ± 2.2 P < 0.001 VATS 5.7 ± 1.2 RATS 4.1 ± 1.1 P < 0.001 VATS 325 RATS 210 P < 0.001	The use of RATS for thymectomy reduces the duration of the operation and the length of hospital stay. This technique also reduces the duration of pleural drainage and the amount of postoperative drainage.

after robotic thymectomy.<sup>22</sup> The authors of another study found no significant differences in a cohort of 21 robotic and 25 thoracoscopic thymectomies for early-stage thymoma, except for a reduced postoperative stay in the former group, but this group had higher hospitalization costs. The operative time and intraoperative blood loss volume did not differ significantly between the two groups. They found a morbidity rate of 8.7%.<sup>16</sup> The morbidity rate of our patients was 11%, with no significant difference between the RATS and VATS groups. However, the mean operative time for robotic surgery was 75 min and was significantly shorter than that for the VATS group. In our clinic, only two patients underwent robotic thymectomy with the left approach. All the other patients underwent RATS with the right approach. We believe that resection of the anterior mediastinal tissue is more comfortable with the use of the right transthoracic approach.

In our study, the number of patients, especially those who underwent thymectomies with the RATS technique, was limited. We believe that further prospective, randomized controlled trials and long-term data are needed to support our results. Moreover, we should observe the

subsequent oncologic outcomes of patients who undergo thymectomies with the RATS technique in future studies.

## 5. Conclusion

RATS thymectomy is equally reliable with VATS, but it is easier to perform surgery compared to thymectomy using VATS. We prefer RATS thymectomy due to the shorter postoperative length of hospital stay, the shorter chest tube drainage time, and the ease of dissection in the surgical procedure.

## Declarations

None.

## Funding

No funding was received for the writing of this report.

## Availability of data and materials

The datasets used and/or analyzed during the current study are available from the corresponding author upon reasonable request.

## Authors' contributions

AŞ collected the data and wrote the manuscript. RA and AN collected and analyzed the data. KE and CB developed the study design and made the main corrections to the manuscript. AŞ performed the surgeries and approved the final manuscript. AŞ, RA, and AN participated in the surgeries. All authors read and approved the final manuscript.

## Consent for publication

Not applicable.

## Ethics approval and consent to participate

The study protocol was approved by the Ethics Committee of Sakarya University, Faculty of Medicine, Turkey.

## Conflicts of interests

The authors declare that they have no competing interests.

## Acknowledgements

All collaborators who contributed to this manuscript were included as authors of the paper. No source of funding is declared for any of the authors.

## Appendix A. Supplementary data

Supplementary data to this article can be found online at <https://doi.org/10.1016/j.asjsur.2019.04.005>.

## References

1. Roviato G, Varoli F, Nucca O, Vergani C, Maciocco M. Videothoracoscopic approach to primary mediastinal pathology. *Chest*. 2000;117:1179–1183.
2. Cheng YJ, Hsu JS, Kao EL. Characteristics of thymoma successfully resected by videothoracoscopic surgery. *Surg Today*. 2007;37:192–196.
3. Melfi F, Fanucchi O, Davini F, et al. Ten-year experience of mediastinal robotic surgery in a single referral centre. *Eur J Cardiothorac Surg*. 2012;41:847–851.
4. Keijzers M, de Baets M, Hochstenbag M, et al. Robotic thymectomy in patients with myasthenia gravis: neurological and surgical outcomes. *Eur J Cardiothorac Surg*. 2015;48:40–45.
5. Toker A, Sonett J, Zielinski M, et al. Standard terms, definitions and policies for minimally invasive resection of thymoma. *J Thorac Oncol*. 2011;6(7):1739–1742.
6. Bayrak Y, Tanju S, Öztürk E, Dilege MŞ. Akciğer kanserinde robotik lobektomi: Erken dönem sonuçlar. *Türk Gogus Kalp Dama*. 2014;22:785–789.
7. Toker A, Özyurtkan MO, Kaba E, Ayalp K, Demirhan Ö, Uyumaz E. Robotic anatomic lung resections: the initial experience and description of learning in 102 cases. *Surg Endosc*. 2016;30(2):676–683.
8. Goldstein SD, Yang SC. Assessment of robotic thymectomy using the myasthenia gravis foundation of America guidelines. *Ann Thorac Surg*. 2010;89:1080–1085.
9. Pandey R, Elakkumanan LB, Garg R, et al. Brachial plexus injury after robotic-assisted thoracoscopic thymectomy. *J Cardiothorac Vasc Anesth*. 2009;23:584–586.
10. Sugarbaker DJ. Thoracoscopy in the management of anterior mediastinal masses. *Ann Thorac Surg*. 1993;11:653–656.
11. Rea F, Marulli G, Bortolotti L, Feltracco P, Zuin A, Sartori F. Experience with the 'da Vinci' robotic system for thymectomy in patients with myasthenia gravis: report of 33 cases. *Ann Thorac Surg*. 2006;11:455–459.
12. Weksler B, Tavares J, Newhook TE, Greenleaf CE, Diehl JT. Robot-assisted thymectomy is superior to transsternal thymectomy. *Surg Endosc*. 2012;11:261–266.
13. Ye B, Li W, Ge XX, et al. Surgical treatment of early-stage thymomas: robot-assisted thoracoscopic surgery versus transsternal thymectomy. *Surg Endosc*. 2014;28:122–126.
14. Ye B, Tantai JC, Ge XX, et al. Surgical techniques for early-stage thymoma: video-assisted thoracoscopic thymectomy versus transsternal thymectomy. *J Thorac Cardiovasc Surg*. 2014;147:1599–1603.
15. Pennathur A, Qureshi I, Schuchert MJ, et al. Comparison of surgical techniques for early-stage thymoma: feasibility of minimally invasive thymectomy and comparison with open resection. *J Thorac Cardiovasc Surg*. 2011;11:694–701.
16. Ye B, Tantai JC, Li W, et al. Video-assisted thoracoscopic surgery versus robotic-assisted thoracoscopic surgery in the surgical treatment of Masaoka stage I thymoma. *World J Surg Oncol*. 2013;11:157.
17. Marulli G, Rea F, Melfi F, et al. Robot-aided thoracoscopic thymectomy for early-stage thymoma: a multicenter European study. *J Thorac Cardiovasc Surg*. 2012;144(5):1125–1130.
18. Cheng YJ, Kao EL, Chou SH. Videothoracoscopic resection of stage II thymoma: prospective comparison of the results between thoracoscopy and open methods. *Chest*. 2005;11:3010–3012.
19. Yellin A. Video-assisted thoracoscopic surgery. *Thymectomy Chest*. 1996;110:578–579.
20. Marulli G, Comacchio GM, Rea F. *Robotic thymectomy J Vis Surg*. 2017;3:68–71.
21. Savitt MA, Gao G, Furnary AP, et al. Application of robotic-assisted techniques to the surgical evaluation and treatment of the anterior mediastinum. *Ann Thorac Surg*. 2005;79:950–955.
22. Rückert JC, Swierzy M, Ismail M. Comparison of robotic and nonrobotic thoracoscopic thymectomy: a cohort study. *J Thorac Cardiovasc Surg*. 2011;141(3):673–677.
23. Qian L, Chen X, Huang J, et al. A comparison of three approaches for the treatment of early-stage thymomas: robot-assisted thoracic surgery, video-assisted thoracic surgery, and median sternotomy. *J Thorac Dis*. 2017;9:1997–2005.