

Surgical removal of a self-expanding metallic stent from jejunum in a patient with Roux-en-Y esophagojejunostomy

¹Ozkan Subasi¹, ¹Kerem Karaman¹, ¹Mehmet Aziret¹, ²Ahmet Tarik Eminler², ²Aydin Seref Koksal², ¹Metin Ercan¹

¹Sakarya University Teaching and Research Hospital, Department of Gastroenterological Surgery, Sakarya, Turkey

²Sakarya University Teaching and Research Hospital, Department of Gastroenterology, Sakarya, Turkey

Copyright © 2020 by authors and Annals of Medical Research Publishing Inc.

Abstract

Self-expanding metallic stent is useful in esophageal perforations, trachea-esophageal fistulas, benign esophageal strictures, and unresectable esophageal cancers. However, self-expanding metallic stent itself has the risk of mucosal necrosis with subsequent perforation and /or trachea-esophageal fistula development –particularly- in long-term usage. Further, gastro-esophageal reflux, stent occlusion, stent migration and intestinal obstruction are other common complications. We report surgical management of a case whose self-expanding metallic stent migrated from the esophagojejunostomy anastomosis towards to the jejunal Y-limp.

Keywords: Esophageal carcinoma; perforation; self-expanding metallic stent; stent migration

INTRODUCTION

Leaks of esophagojejunostomy anastomosis are serious complications especially when the anastomosis is located intrathoracic. Endoscopic stent placement is crucial in treating these defects and its proven that morbidity and mortality is reduced with this intervention (1,2). Self-expanding metallic stent placement is also useful in the cases of esophageal perforations, trachea-esophageal fistulas, benign esophageal strictures due to caustic fluid ingestion, and for passage of unresectable esophageal cancers (3). On the other hand, covered expanding metallic stent itself has the risk of pressure on mucosa which can leads to mucosal necrosis with subsequent perforation and / or trachea-esophageal fistula development –particularly- in long-term usage. Further, gastro-esophageal reflux, stent occlusion, stent migration and intestinal obstruction are other common complications (4,5). We report a case whose stent migrated from the esophagojejunostomy anastomosis towards to the jejunal Y-limp.

CASE REPORT

A 63-year-old male patient was admitted with complains of dysphagia and weight loss. His endoscopic exam revealed a mass at the lower esophago-gastric junction (Siewert Type-II). The histopathological diagnosis of

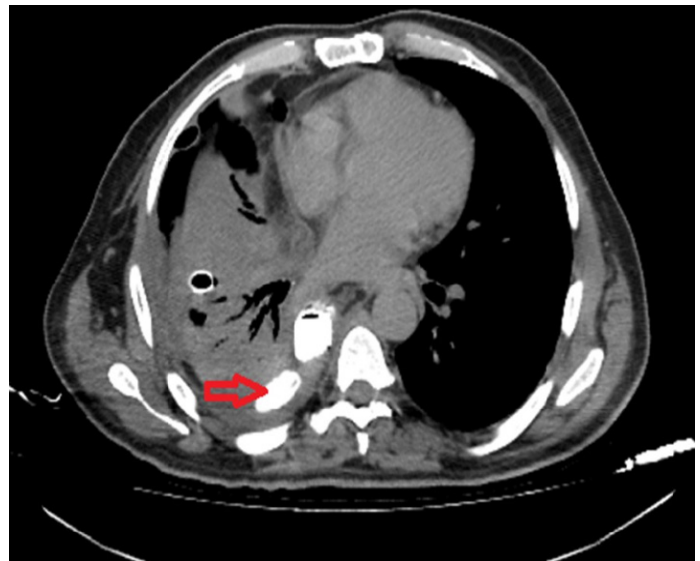


Figure 1. Leak of the esophago-jejunosomy anastomosis shown by computerized tomography

the biopsy taken from the mass was adenocarcinoma. It was decided to trans-thoracic Ivor-Lewis esophago-gastrectomy. Following the esophago-gastric resection, a Roux-en-Y esophago-jejunosomy was created for the gastrointestinal continuity. In the postoperative period, a leak occurred in the esophago-

Received: 17.11.2019 Accepted: 02.02.2020 Available online: 02.04.2020

Corresponding Author: Ozkan Subasi, Sakarya University Teaching and Research Hospital, Department of Gastroenterological Surgery, Sakarya, Turkey E-mail: osubasi25@hotmail.com

jejunostomy anastomosis on the fifth postoperative day (Figure 1). An expandable stent was inserted endoscopically. The stent was left in place for more than 2 months until the defect was closed. When it was decided to remove the stent via endoscopic route, we detected that the stent was not where it should be. An upper esophagogram showed that the stent moved to the anastomotic line of the Y limb and was found to be attached to the stump of the Y limb which did not allow the stent to past more distally (Figure 2).

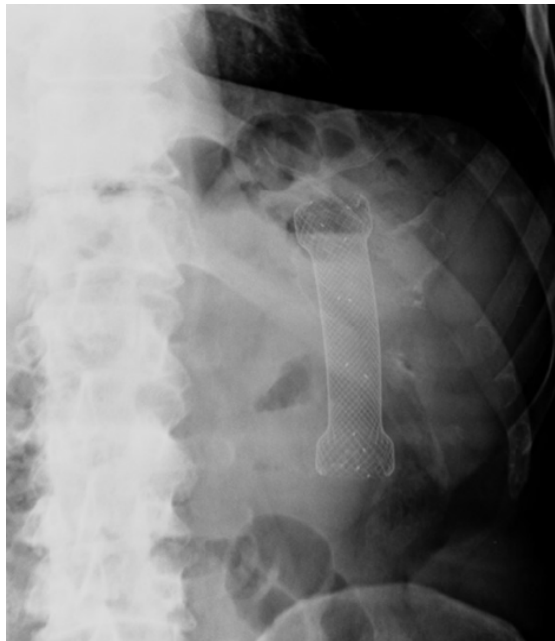


Figure 2. Esophagogram showing the stent migration

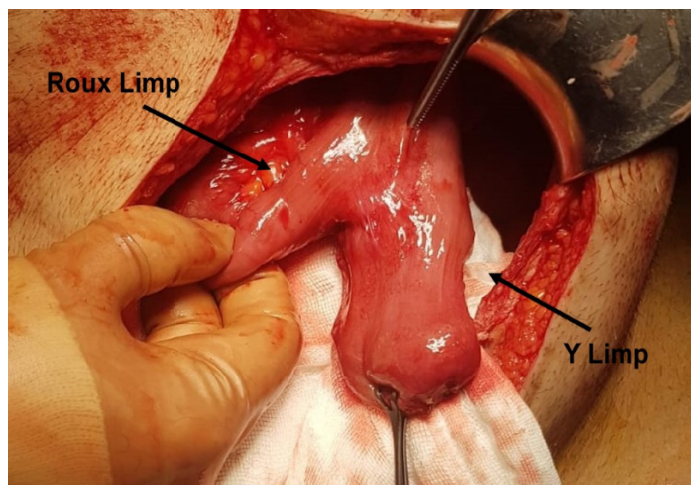


Figure 3. Attachment of the stent to the stump of the Y limb

Patient's vital signs and laboratory findings were in normal ranges. He had no signs or symptoms other than vague left upper quadrant pain. It was not considered appropriate to leave the stent in place due to the risk of possible complications such as stent migration, perforation or fistulation. We concluded to explorative laparotomy after two unsuccessful endoscopic

attempts for removing of the stent. During surgery, the tip of the stent was attached at the stump of the Y limb (Figure 3). The stump of the Y limb was opened and the stent was extracted (Figure 4). The stump was reclosed using linear stapler (Figure 5). Patient's postoperative course was uneventful. Oral consumption was started on the 3th postoperative day and he was discharged at the 6th postoperative day.

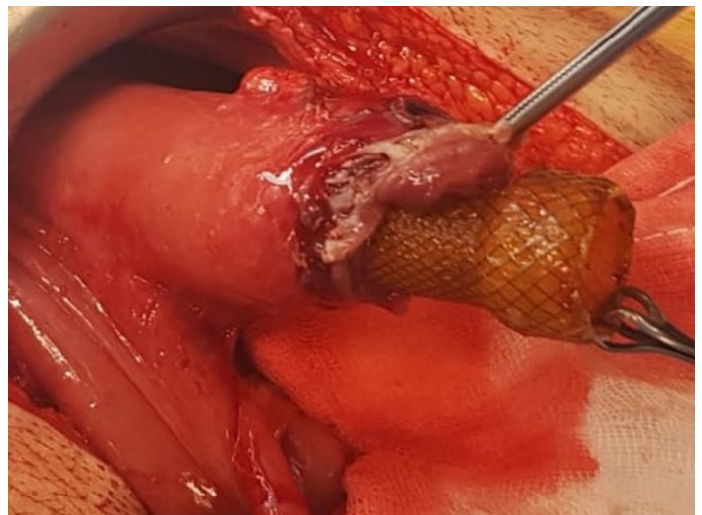

Figure 4. Extraction of the stent from the stump of Y Limb

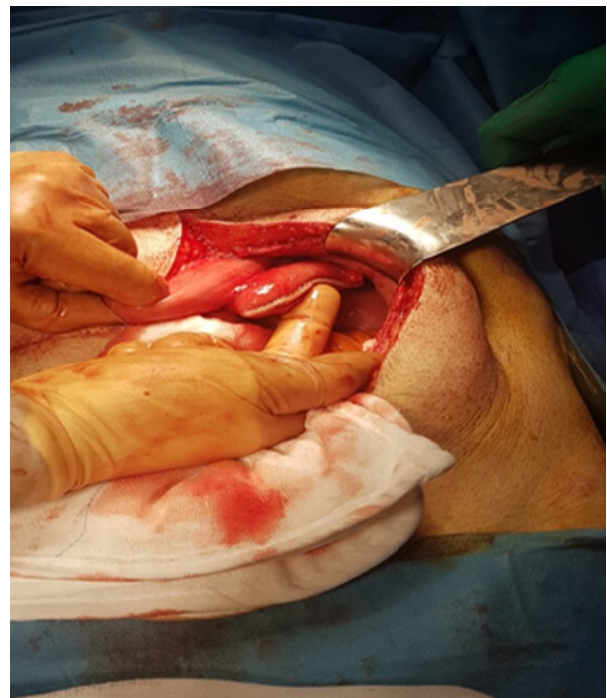

Figure 5. Closure of the stump with linear stapler.

DISCUSSION

Migration of the stent is a problematic complication which usually occurs when it's not enough expands and sufficiently covers the lumen. Shrinking of the tumor as a response to chemo-radiotherapy, stent malposition, and excessive dilatation of the structured segment before

stent placement are possible causes of stent migration (6,7). In the literature, few cases are reported with small bowel perforation due to stent migration (8-14). In the present case, the stent was probably passed to distal due to healing of inflammatory process and regression of the edema at the anastomotic line.

In the existence of stent migration, the first step should be the detection of stent localization by imaging methods such as abdominal X-ray and computerized tomography. Endoscopic stent removal is the treatment of choice. However, it's not always possible to remove the stent by endoscopic route and has sometimes the risk of mucosal tears and perforations (5,8). If endoscopy fails, surgical removal –whether laparoscopic or open- should be preferred to conservative management. Because, a waiting policy for the stent to pass from terminal ileum to the cecum is unlikely and stent related complications during this process such as perforation or fistula development is much more difficult to manage (15).

CONCLUSION

In conclusion, stent migration is a rare but serious complication which should be meticulously handled. Endoscopic removal is the first choice of treatment. However, surgical removal should be preferred to conservative management if endoscopic attempts are unsuccessful.

Competing interests: The authors declare that they have no competing interest.

Financial Disclosure: There are no financial supports.

Ozkan Subasi ORCID: 0000-0002-6727-3463

Kerem Karaman ORCID: 0000-0003-0143-9712

Mehmet Aziret ORCID: 0000-0001-6758-7289

Ahmet Tarik Eminler ORCID: 0000-0003-1402-5682

Aydin Seref Koksal ORCID: 0000-0001-5623-6109

Metin Ercan ORCID: 0000-0003-0633-3052

REFERENCES

1. Roy-Choudhury SH, Nicholson AA, Wedgwood KR, et al. Symptomatic malignant gastroesophageal anastomotic leak: management with covered metallic esophageal stents. *AJR Am J Roentgenol* 2001;176:161-5.
2. Therasse E, Oliva VL, Lafontaine E, et al. Balloon dilation and stent placement for esophageal lesions: indications, methods, and results. *Radiographics* 2003;23:89-105.
3. Sharma P, Kozarek R. Practice Parameters Committee of American College of Gastroenterology. Role of esophageal stents in benign and malignant diseases. *Am J Gastroenterol* 2010;105:258-73.
4. Rabenstein T. Palliative Endoscopic Therapy of Esophageal Cancer. *Viszeralmedizin* 2015;31:354-9.
5. Turkyilmaz A, Eroglu A, Aydin Y, et al. Complications of metallic stent placement in malignant esophageal stricture and their management. *Surg Laparosc Endosc Percutan Tech* 2010;20:10-5.
6. Keller R, Flieger D, Fischbach W, et al. Self-expanding metal stents for malignant esophagogastric obstruction: experience with a new design covered nitinolstent. *J Gastrointest Liver Dis* 2007;16:239-43.
7. Pavlidis TE, Pavlidis ET. Role of stenting in the palliation of gastroesophageal junction cancer: A brief review. *World J Gastrointest Surg* 2014;6:38-41.
8. Henne TH, Schaeff B, Paolucci V. Small-bowel obstruction and perforation. A rare complication of an esophageal stent. *Surg Endosc* 1997;11:383-4.
9. Kim HC, Han JK, Kim TK, et al. Duodenal perforation as a delayed complication of placement of an esophageal stent. *J Vasc Interv Radiol* 2000;11:902-4.
10. Reddy VM, Sutton CD, Miller AS. Terminal Ileum Perforation as a Consequence of a Migrated and Fractured Oesophageal Stent. *Case Rep Gastroenterol* 2009;15:61-6.
11. Bay J, Penninga L. Small bowel ileus caused by migration of oesophageal stent. *Ugeskr Laeger* 2010;172:2234-5.
12. Zhang W, Meng WJ, Zhou ZG. Multiple perforations of the jejunum caused by a migrated esophageal stent. *Endoscopy* 2011;43:145-6.
13. Karagul S, Yagci MA, Ara C, et al. Small bowel perforation due to a migrated esophageal stent: Report of a rare case and review of the literature. *Int J Surg Case Rep* 2015;11:113-6.
14. 14. Tasleem SH, Inayat F, Ali NS, et al. Small Bowel Perforation Secondary to Esophageal Stent Migration: A Comparative Review of Six Cases. *Cureus* 2018;10:3455.
15. De Palma GD, Iovino P, Catanzano C. Distally migrated esophageal self-expanding metal stents: wait and see or remove? *Gastrointest Endosc* 2001;53:96-8.