

## An Unusual Recurrence of Miller Fisher Syndrome: Three Times in Eight Years

Zeynep ÖZÖZEN AYAS<sup>1</sup> , Yeşim GÜZEY ARAS<sup>1</sup> , Belma DOĞAN GÜNGEN<sup>2</sup> 

<sup>1</sup>Sakarya University Training and Research Hospital, Department of Neurology, Sakarya, Turkey

<sup>2</sup>Reyap Hospital, Neurology, İstanbul, Turkey

### ABSTRACT

Miller Fisher Syndrome (MFS) is an acute, autoimmune polyneuropathy usually associated with a good prognosis which is clinically characterized by ataxia, ophthalmoplegia, and areflexia. MFS has a monophasic course, double recurrence can be seen in rare cases. But three attacks are very rare. In this article, we discussed a rare case of MFS and approach to the treatment that recurred 3 times within a period of 8 years. It is

emphasized that MFS cases may occur a recurring pattern, and plasma exchange should be definitely tried as a therapeutic approach when clinical deterioration occurs under intravenous immunoglobulin (IVIg) therapy.

**Keywords:** Miller Fisher Syndrome, recurrence, treatment

**Cite this article as:** Özözen Ayas Z, Güzey Aras Y, Doğan Güngen B. An Unusual Recurrence of Miller Fisher Syndrome: Three Times in Eight Years. Arch Neuropsychiatry 2020;57:78-79.

### INTRODUCTION

Miller Fisher Syndrome (MFS) is a subgroup of Guillain-Barré syndrome (GBS) and clinically characterized by ataxia, ophthalmoplegia, and areflexia. MFS is an acute, autoimmune polyneuropathy usually associated with a good prognosis. Despite having a monophasic course, it rarely tends to recur. In this article, we discussed a rare case of MFS that recurred 3 times within a period of 8 years.

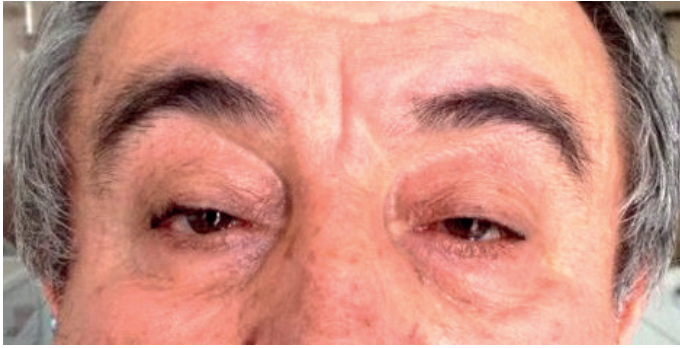
### CASE REPORT

A 71-year-old man was admitted to hospital with gait disorder and drooping eyelids after an upper respiratory tract infection in 2009. He had bilateral ptosis, dysphonic speech, minor paresia, and loss of deep tendon reflexes (DTR) in upper and lower extremities. At that time a cerebrospinal fluid (CSF) examination had revealed albuminocytological dissociation; and an electrophysiological examination had indicated sensorimotor polyneuropathy affecting motor and sensory nerves, with preserved sural nerve response but lost F responses. He had been administered intravenous immunoglobulin (IVIg) for 5 days with MFS diagnosis and slight improvement in tetraparesis. Three days after the cessation of treatment, however, his neurological examination had deteriorated, and he was treated with plasma exchange (PE) therapy for 5 days with partial benefit. Thereafter, he had participated in a physiotherapy program, and had completely improved 3 months after. In 2013 he presented to our hospital after a second attack characterized by drooping eyelids, numbness and weakness of extremities. Three months prior to that presentation he had begun suffering severe intermittent diarrheal attacks. He had bilateral ptosis, limited lateral gaze in both eyes, disarthric speech, tetraparesia (bilateral biceps 5-/5, right triceps 4/5, left triceps 3+/5, bilateral ankle flexors 5-/5, lower extremity muscle strengths 4/5), hyporeflexia in upper extremities, and areflexia in lower extremities

(Figure 1). CSF analysis revealed a glucose level of 92 mg/dl (40–70 mg/dL) and a protein level of 436 mg/dL (150–450 mg/dL) and antiGQ1b was found negative. Autoimmune paraneoplastic antibody testing detected serum anti-Yo antibody positivity. A malignancy screening consisting of serum tumor marker measurement, abdominal US, and thoracic CT examination did not yield a specific diagnosis. A provisional diagnosis of MFS was made, for which the patient was treated with IVIg at a dose of 0.4 gr/kg. As he developed dysphagia on the 3th and on the 4th day of treatment he sustained cardiac and respiratory arrest, and was successfully resuscitated, stabilized, and connected to mechanical ventilation. He was monitored under mechanical ventilation for 14 days, and additionally, underwent PE for 5 days. After he was stabilized, and observed for an additional 10 days, after which he was discharged with partial improvement of ptosis and minor tetraparesia (4+/5, 5-/5). Having attended a physiotherapy program, the patient had his muscle strengths almost returned to normal. He was admitted to our hospital with gait disorder and drooping eyelids in 2016, for the third time. He had bilateral semiptosis with both eyelids being at the level of pupilla, bilaterally limited lateral gaze in conjugated eye movements, trunk ataxia, full extremity muscle strengths, and abolic DTR. Hemogram, biochemistry tests, and intracranial images were normal. As he refused lumbar puncture (LP), CSF examination was not possible. An electrophysiological study revealed a sensorineural type polyneuropathy which was characterized by lost sensory and F responses but preserved sural nerve response. IVIg was begun for 5 days. He was discharged with near-complete correction of ptosis and ataxia on the 12th day.

### DISCUSSION

MFS cases were published in 1956 by the physician who named the syndrome (1). New criteria have been studied for defining subtypes.



**Figure 1.** The patient had bilateral ptosis.

A recent study indicated that electrophysiological studies are more important in phenotypic description for defining subtype and determining prognosis according to a new GBS clinical classification (2).

Ataxia, ophtalmoplegia, and areflexia are the classical signs of the syndrome. Its etiopathogenesis include demyelination and axonal injury in peripheral nerves, spinal roots, and cranial nerves due to autoimmunity after an infection.

Studies about the signs of MFS have provided evidence of an injury to Group Ia neurons in the dorsal root ganglia by circulating antibodies as the cause of ataxia (3). Ophtalmoplegia in MFS is rather bilateral and symmetrical in character. A case with unilateral onset but bilateral progression was also reported, too (4). Our patient had ophtalmoplegia in his second and third attacks. Areflexia may not exist in all cases. Normal or increased reflex responses can be seen. Bilateral ptosis is a rare sign. Our patient had bilateral ptosis in all attacks. A study demonstrated that signs and symptoms in subsequent attacks were milder than those in the first attack (5). Our patient's first attack was characterized by ptosis, dysphonic speech, minor paresthesia and loss of DTR in extremities; the second attack by ptosis, limited lateral gaze, dysarthric speech, tetraparesia, and areflexia; and the third attack by semiptosis, ataxia, and ophtalmoplegia. It was noted that the third attack had a milder course than the second one.

MFS typically has a monophasic course. However, it rarely tends to recur (6). The number of recurrences is usually limited to two. The study detected recurrences in 4 of 34 patients, and the first attacks of the patients with recurrent MFS tended to occur at a younger age (5). Our patient had his first attack at the age of 63 years.

Riche et al. reported an antiGQ1b positive case with 3 attacks within 16 years (7). Our patient suffered 3 attacks in a period of 8 years. AntiGQ1b was only found negative in the second attack. One study reported an inter-attack period of 2.5–12.5 years (8). Our patient's first and second attacks were spaced by 4 years and the second and third attacks by 3 years.

GBS and its forms may rarely be paraneoplastic in nature. According to the criteria for paraneoplastic neurological syndromes (PNS) published by Graus et al., the presence of a non-classical neurological syndrome and a well-defined onconeural antibody in the absence of cancer is definitely defined as a PNS (9). Our patient had recurrent MFS, a non-classical neurological syndrome, and anti-Yo positivity, a well-defined onconeural antibody. Therefore, our patient has been regularly screened for malignancy for the possibility of a PNS.

MFS usually portends a favorable prognosis. However, our patient had frequent recurrences and a poor clinical course, and he required mechanical ventilatory support at intensive care unit. The available treatment options include IVIg and PE. However, some contrasting views exist in the literature with regard to the treatment. Mori et al. examined

92 patients with MFS and treatment (28 IVIg, 23 PE, 41 none). They found that IVIg therapy slightly hastened the improvement of ophtalmoplegia and ataxia, but the times to disappearance of the symptoms were comparable in all groups (10). They were of the opinion that IVIg and PE did not alter patient outcomes due to the inherent favorable prognosis of the disorder (10). Our patient had not sufficiently benefited from IVIg therapy and he had even progressed in the first two attacks, but showed dramatic improvement with subsequent PE treatment. Our patient had response to the standard dose IVIg at last attack.

His all attacks were characterized by a severe clinical course and an antecedent infection. He showed a poor response to IVIg but a dramatic response to PE at the first two attacks. In clinical practice, physicians should remember that, albeit rare, MFS cases may demonstrate a recurring pattern, and PE should be definitely tried as a therapeutic approach when clinical deterioration occurs under IVIg.

**Informed Consent:** The written informed consent was obtained from the patient.

**Peer-review:** Externally peer-reviewed.

**Author Contributions:** Concept - ZÖA, YGA, BDG; Design - ZÖA, YGA, BDG; Supervision - ZÖA, YGA, BDG; Resource - ZÖA, YGA, BDG; Materials - ZÖA, YGA, BDG; Data Collection and/ or Processing - ZÖA, YGA, BDG; Analysis and/ or Interpretation - ZÖA, YGA, BDG; Literature Search - ZÖA, YGA, BDG; Writing - ZÖA, YGA, BDG; Critical Reviews - ZÖA, YGA, BDG.

**Conflict of Interest:** There are no conflicts of interest.

**Financial Disclosure:** The authors declared that this study has received no financial support.

## REFERENCES

1. Fisher M. An unusual variant of acute immune polyneuritis (syndrome of ophtalmoplegia, ataxia, and areflexia). *N Engl J Med* 1956;255:57–65. [\[CrossRef\]](#)
2. Hiew FL, Ramlan R, Viswanathan S, Puvanarajah S. Guillain-Barre Syndrome, variants&forms fruste: Reclassification with new criteria. *Clin Neurol Neurosurg* 2017;158:114–118. [\[CrossRef\]](#)
3. Kuwabara S. Pathophysiology of Ataxia in Fisher Syndrome. *Brain Nerve* 2016;68:1411–1414. [\[CrossRef\]](#)
4. Bukhari S, Taboada J. A case of Miller Fisher Syndrome and Literature Review. *Cureus* 2017;9:e1048. [\[CrossRef\]](#)
5. Ishii J, Yuki, N, Kawamoto M, Yoshimura H, Kusunoki S, Kohara N. Recurrent Guillain-Barre syndrome, Miller Fisher syndrome and Bickerstaff brainstem encephalitis. *J Neurol Sci* 2016;364:59–64. [\[CrossRef\]](#)
6. Gür S, Tunçer ÖG, Tolun R, Altındağ E, Krespi Y. Recurrent Miller-Fisher Syndrome: A case report. *Arch Neuropsychiatry* 2011;48:281–284. [\[CrossRef\]](#)
7. Riche G, Caudie C, Vial C, Bourrat C. Recurrent Miller Fisher syndrome and anti-GQ1b antibodies. *Rev Med Interne* 1998;19:192–195. [\[CrossRef\]](#)
8. Chida K, Nomura H, Konno H, Takase S, Itoyama Y. Recurrent Miller Fisher syndrome: clinical and laboratory features and HLA antigens. *J Neurol Sci* 1999;165:139–143. [\[CrossRef\]](#)
9. Graus F, Delattre JY, Antoine JC, Dalmau J, Giometto B, Grisold W, Honnorat J, Smitt PS, Vedeler Ch, Verschuuren JJ, Vincent A, Voltz R.. Recommended diagnostic criteria for paraneoplastic neurological syndromes. *J Neurol Neurosurg Psychiatry* 2004;75:1135–1140. [\[CrossRef\]](#)
10. Mori M, Kuwabara S, Fukutake T, Hattori T. Intravenous immunoglobulin therapy for Miller Fisher syndrome. *Neurology* 2007;68:1144–1146. [\[CrossRef\]](#)